

Category 4: Class II Division 2 malocclusion with deep overbite

Baharak Fooladi,^a Tarryn MacCarthy,^b Tracy Maloney,^c and Lokesh Suri^d

Boston, Mass

This case report was part of the resident display of cases sponsored by the College of Diplomates of the American Board of Orthodontics at the annual session of the American Association of Orthodontists, May 20-24, 2005, in San Francisco, Calif. (*Am J Orthod Dentofacial Orthop* 2007;132:252-9)

SUMMARY OF TREATMENT

Case report category: 4

Patient's date of birth: 12/19/1986

Age: 15 years 9 months

PRETREATMENT RECORDS

Date of records: 09/13/02 (Figs 1-4, Table)

Diagnosis

Skeletal: Hypodivergent growth pattern, vertical maxillary excess, increased transverse width of maxilla.

Dental: Angle Class II Division 2 malocclusion, unilateral buccal crossbite (Brodie bite) of maxillary left premolars and second molar, asymmetric maxillary and mandibular arches, 100% deep and impinging overbite, mandibular crowding (6 mm), excessive overjet (6 mm), upper midline 1 mm to the left of facial midline.

Facial: Brachycephalic facial pattern, symmetrical, orthognathic profile, full lips with an acute nasolabial angle (79°), deficient lower third anterior face height, 5-mm gingival display on smiling with minimal incisor display.

Other: Learning disability, developmentally delayed, poor oral hygiene.

Chief complaint: Severe overbite; worry about long-term damage to gums and teeth.

Treatment plan

Correct deep anterior impinging overbite and posterior Brodie bite, coordinate arches, and normalize Class II dental malocclusion with comprehensive orthodontic treatment. Band maxillary molars and deliver anterior bite plate to achieve disocclusion and eliminate palatal impingement of mandibular incisors. Intrusion arch to be used at the beginning of treatment. Deliver cervical headgear to be worn by the patient 12 to 14 hours per day to distalize maxillary molars. Band and bond mandibular arch and sequentially level curve of Spee. Create space for mandibular left second premolar. Bond maxillary incisors and use 2 × 4 intrusion utility arch. Coordinate arch forms and use cross elastics to correct Brodie bite. Class II elastics to be used as needed. Detailing, remove appliances, and retain.

Treatment

Patient cooperation and oral hygiene were to be evaluated before starting treatment. Use bite plate to disocclude the dentition and eliminate mandibular incisor impingement on the palate (Fig 5). Deliver cervical headgear and instruct patient to wear it at least 12 to 14 hours per day. Use intrusion arch to intrude maxillary anterior teeth and reduce gingival display. Level mandibular arch with sequential archwires and open space for mandibular left second premolar. Coordinate archwires and use cross elastics to eliminate buccal crossbite on left side. Correct sagittal discrepancy of Class II end-on molar relationship. Class II elastics and final detailing of occlusion as needed. Remove appliances and deliver retainers.

Treatment initiated: 11/08/02

Appliance removal: 11/19/04

Active treatment time: 24 months

POSTTREATMENT RECORDS

Date of records: 5/06/05 (Figs 6-11).

From the Department of Orthodontics, School of Dental Medicine, Tufts University, Boston, Mass.

^aFormer resident; private practice, New York, NY.

^bPrivate practice, Lynnfield, Mass.

^cAssistant clinical professor.

^dAssistant professor.

Reprint requests to: Lokesh Suri, Department of Orthodontics, DHS-2, Tufts University School of Dental Medicine, One Kneeland St, Boston, MA 02111; e-mail, lokesh.suri@tufts.edu.

Submitted, November 2005; revised and accepted, January 2006.

0889-5406/\$32.00

Copyright © 2007 by the American Association of Orthodontists.

doi:10.1016/j.ajodo.2006.01.031

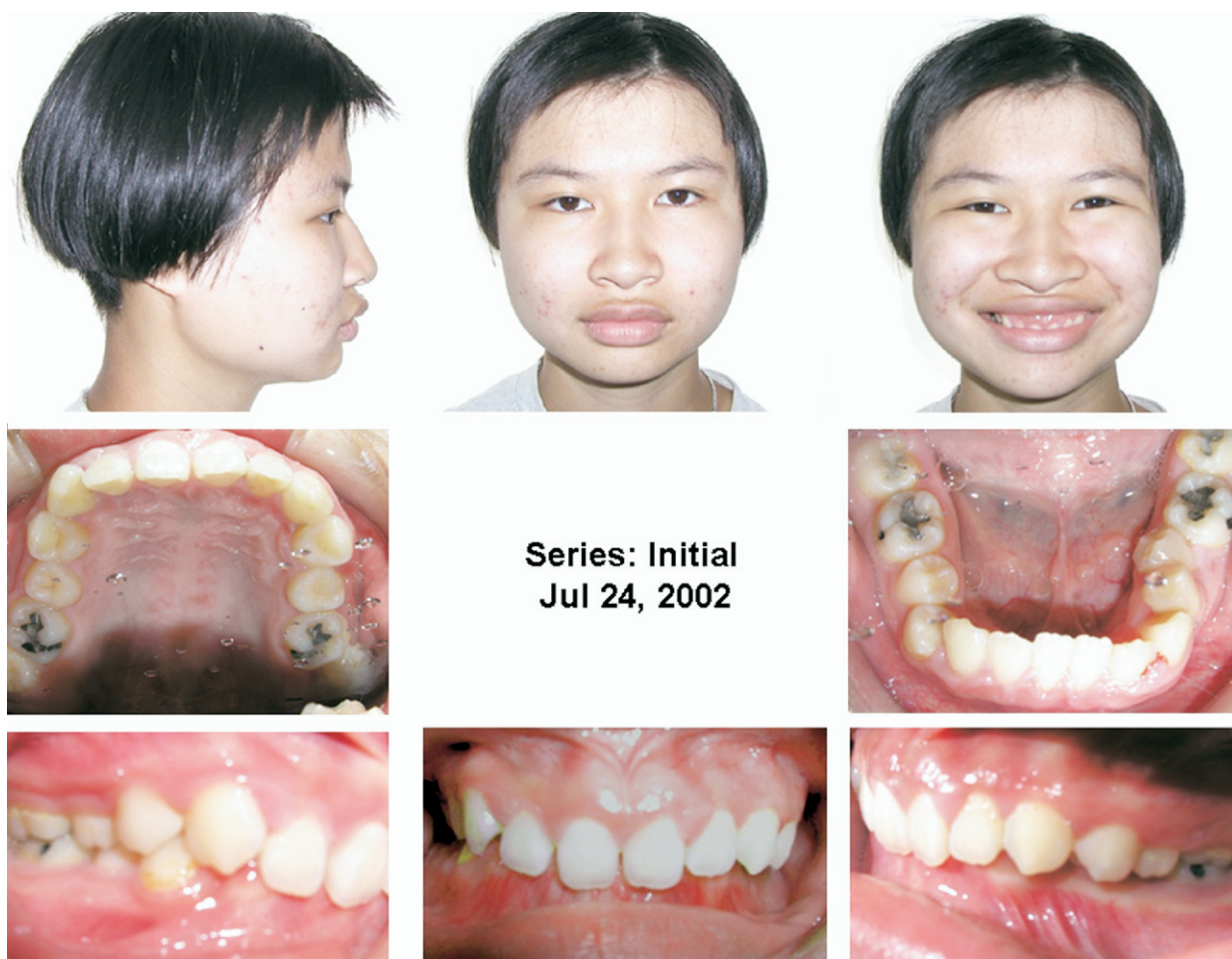

Fig 1. Pretreatment photographs.

Retention: Maxillary Hawley and mandibular bonded 3 × 3 retainers.

Retention completion: Ongoing

Retention duration: Indefinite

HISTORY AND ETIOLOGY

The patient's medical and dental histories were noncontributory to the malocclusion. Her problem was primarily skeletal. Her strong musculature tended to deepen her bite. The etiology of the malocclusion was probably multifactorial, but hereditary factors might have played a role.

DIAGNOSIS

Skeletal: Hypodivergent growth pattern, maxillary vertical and transverse excess.

Dental: Angle Class II Division 2 malocclusion, unilateral left posterior buccal crossbite, deep imping-

ing overbite, severe overjet (9 mm), mandibular crowding (6 mm).

TREATMENT PLAN

The patient was to be observed to evaluate her ability to cooperate before active treatment. The plan included correction of deep anterior impinging overbite and posterior Brodie bite, arch coordination, and normalization of Class II dental malocclusion with comprehensive orthodontic treatment. Band maxillary molars and deliver anterior bite plate to achieve disocclusion and eliminate palatal impingement of the mandibular incisors. Maxillary incisors and 2 × 4 intrusion utility arch to be used at beginning to evaluate the patient's ability to cope with fixed appliances. Deliver cervical headgear to be worn 12 to 14 hours per day to distalize maxillary molars. Band and bond mandibular arch and sequentially level the curve of

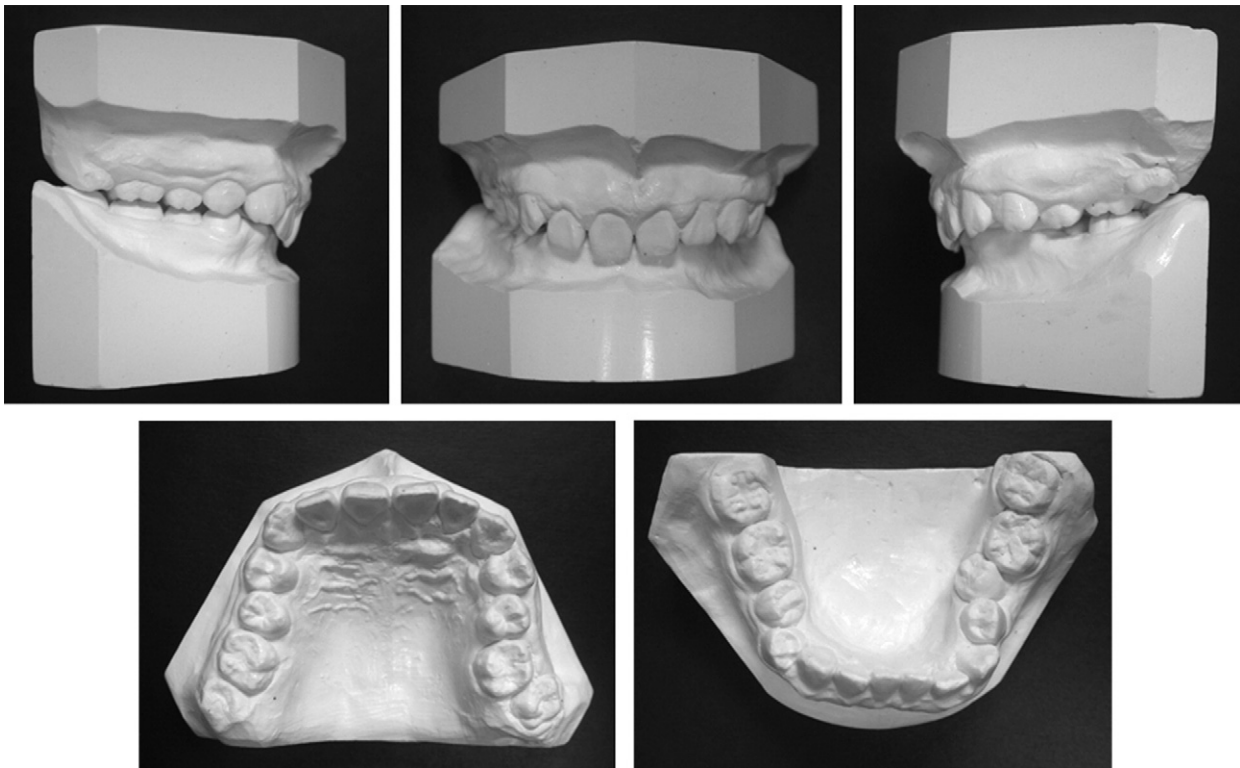


Fig 2. Pretreatment dental casts.

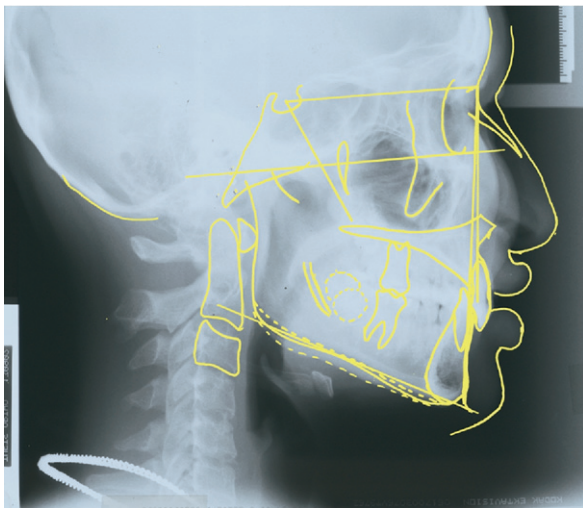


Fig 3. Pretreatment cephalometric tracing.

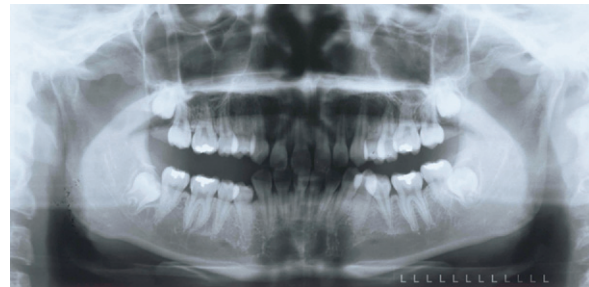

Fig 4. Pretreatment panoramic radiograph.

Spee. Create space for mandibular left second premolar. Coordinate arch forms and use cross elastics to correct the Brodie bite. Class II elastics to be used as needed. Detailing, remove appliances, and retain.

SPECIFIC OBJECTIVES OF TREATMENT

Maxilla

A-P: Hold.

Mandible

A-P: Allow for maximum A-P expression of growth, remove interferences to distally trapped mandible.

Vertical: Increase via extrusion and uprighting of posterior teeth.

Table. Cephalometric summary

Area	Measurement	A ¹	A ² (progress)	B	*Difference A ¹ –B
Maxilla to cranial base	SNA angle (°)	86	83	82	4
Mandible to cranial base	SNB angle (°)	84	81	79.5	4.5
	Y-axis (°)	65	65	63	2
	SN-Go-Gn (°)	26.5	31	32	5.5
	FMA (°)	25	28	25	0
Maxillomandibular	ANB angle (°)	3	2	2.5	0.5
Maxillary dentition	1 to NA (mm)	0	10	9	9
	1 to SN (°)	86	107	104	18
	6-6 (mm) (casts) between central fossae	48.5	53	50	1.5
Mandibular dentition	1 to NB (mm)	-2.5	8	8	10.5
	1 to Go-Gn (°)	70	101	103	33
	6-6 (mm) (casts)	43	43.5	43	0
	3-3 (mm) (casts)	30	29	28	2
	Soft tissue	Esthetic plane (upper lip/lower lip) (mm)	-4/0.5	2/4	1/3

A¹, Pretreatment records; A², interim or progress records if indicated; B, final records.

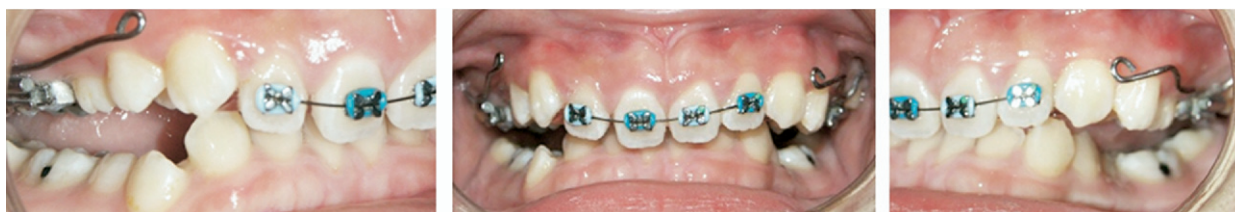

Fig 5. Progress photographs showing biteplate.

Maxillary dentition

A-P: Distalize maxillary molars, procline maxillary incisors.

Vertical: Increase with extrusion of posterior teeth; anterior teeth to be intruded.

Intermolar width: Decrease transverse width across canines, premolars, and second molars and increase across first molars.

Mandibular dentition

A-P: Procline incisors.

Vertical: Increase via extrusion of posterior teeth and intrusion of anterior teeth.

Intermolar/intercanine width: Constrict intercanine width.

Facial esthetics: Increase lower anterior face height, decrease gingival display.

APPLIANCES

Full edgewise appliance (American IBD prescription) with anterior .018 × .025-in and posterior .022 × .028-in bracket slot; cervical pull headgear worn 12 to 14 hours per day; anterior bite plane, and Class II 5/16-oz elastics.

TREATMENT PROGRESS

Because of poor oral hygiene and history of delayed maturation with learning disability, the patient and the parent were advised that treatment would begin after evaluation of the patient's cooperation and improvement in home care. After 6 weeks of evaluation, the maxillary molars were banded and a bite plate delivered. The patient's home care and cooperation improved significantly over the next few weeks. Subsequently, the mandibular arch was banded with IBD bidimensional edgewise appliances: anterior .018 × .025-in and posterior .022 × .028-in bracket slots. Sequentially larger wires were used to level the mandibular arch, and a push coil was used to open space for the mandibular left second premolar. Sectional .014-in stainless steel archwire was used to level the maxillary anterior teeth followed by a .016 × .022-in intrusion 2 × 4 arch. The patient wore cervical headgear to distalize the maxillary molars. The remaining maxillary teeth were bonded, and cross elastics were used to upright the mandibular posterior teeth while the maxillary bite plate was trimmed on the palatal to allow for arch coordination. Class II elastics were used with finishing archwires of

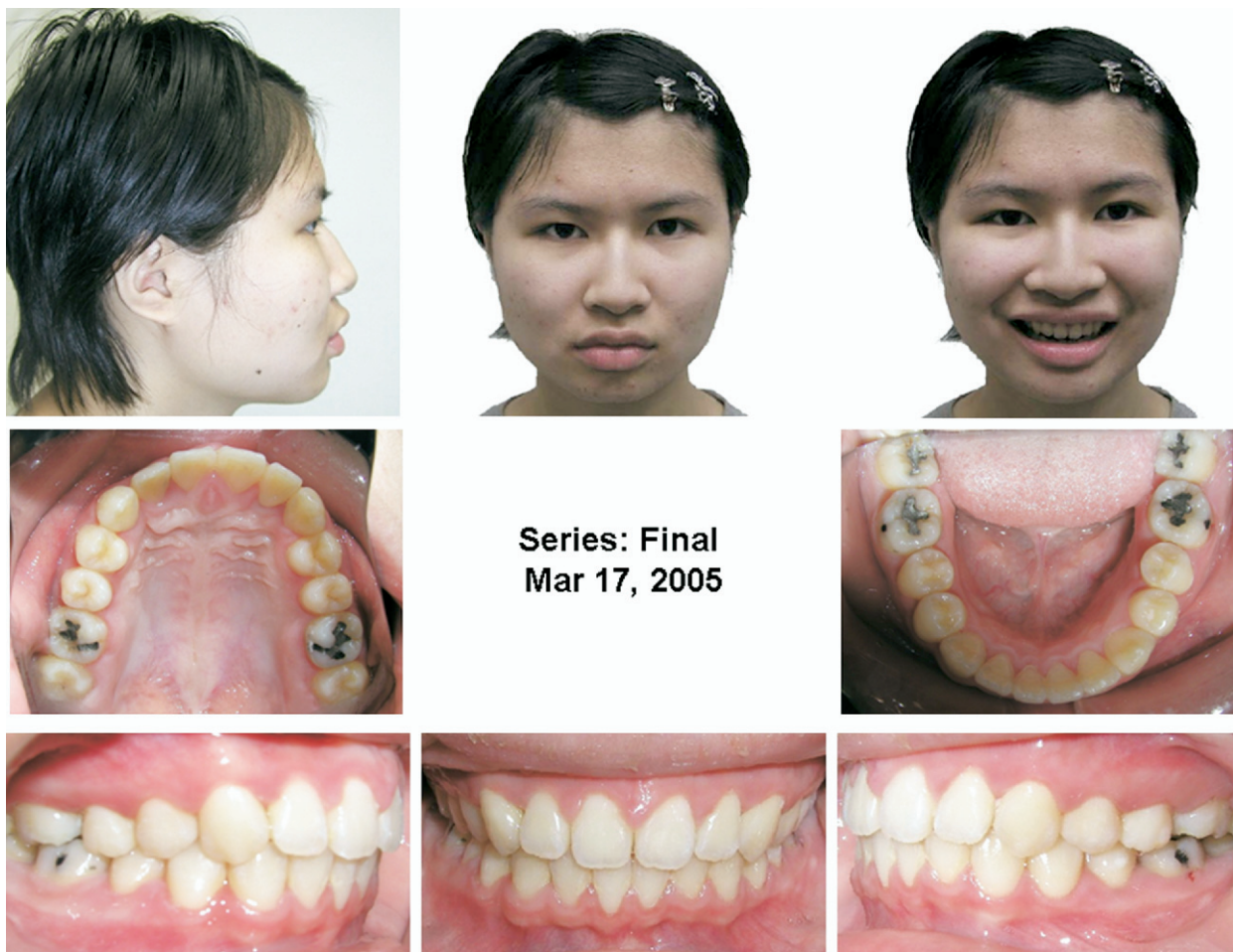

Fig 6. Posttreatment photographs.

16 × 22 stainless steel. Appliances were removed and retainers delivered.

RESULTS ACHIEVED

Maxilla

A-P: Retracted (SNA angle decreased due to lingual root torque in maxillary incisors).

Vertical: Increased via posterior extrusion and anterior intrusion.

Mandible

A-P: SNB angle reduced due to lingual root torque.

Vertical: Increased via posterior extrusion and anterior intrusion.

Maxillary dentition

A-P: Incisors proclined.

Vertical: Increased.

Intermolar width: Increased.

Inter canine: Decreased.

Mandibular dentition

A-P: Incisors proclined.

Vertical: Increased.

Intermolar width: Increased.

Inter canine width: Decreased.

FACIAL ESTHETICS

The objectives of increasing lower anterior facial height and decreasing gingival display were obtained. Facial esthetics were dramatically improved on smiling. The patient has 90% maxillary incisal display with no gingival display upon smiling. Her profile did not change significantly.

RETENTION

A maxillary Hawley retainer was delivered, and the patient was instructed to wear it full time for the first 6

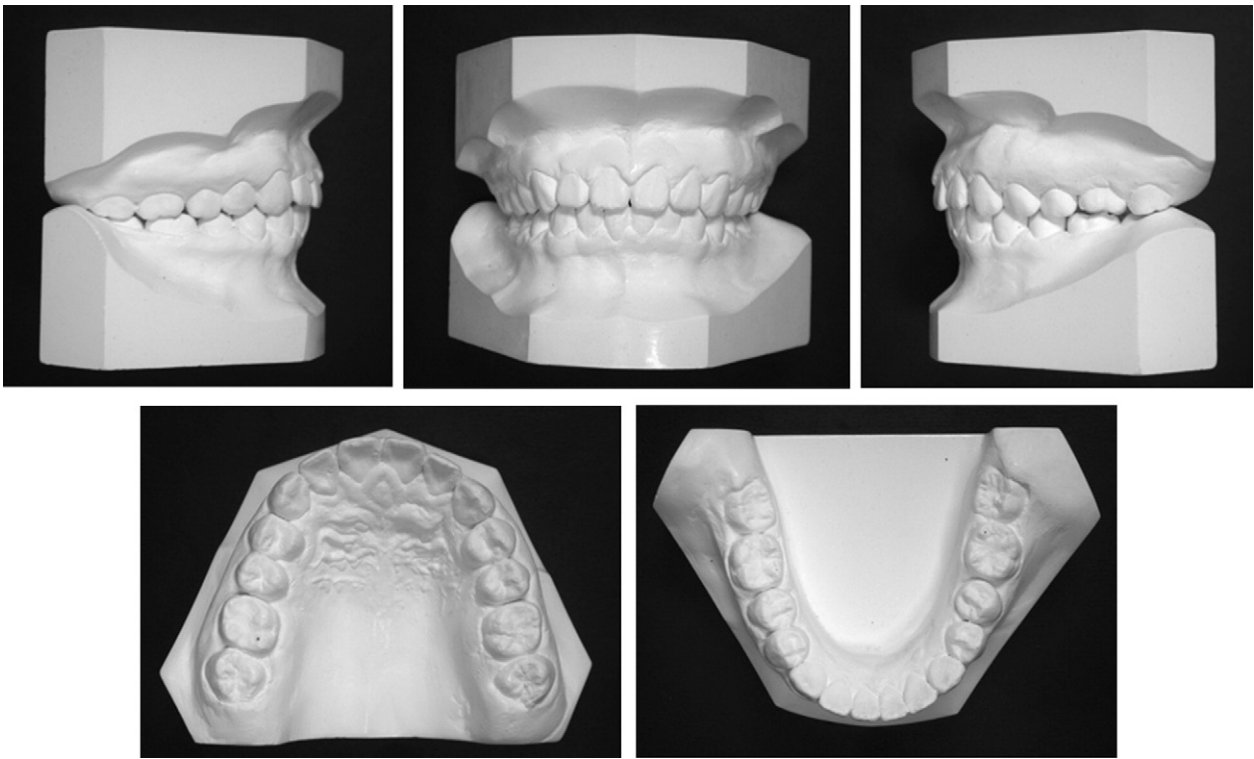


Fig 7. Posttreatment dental casts.

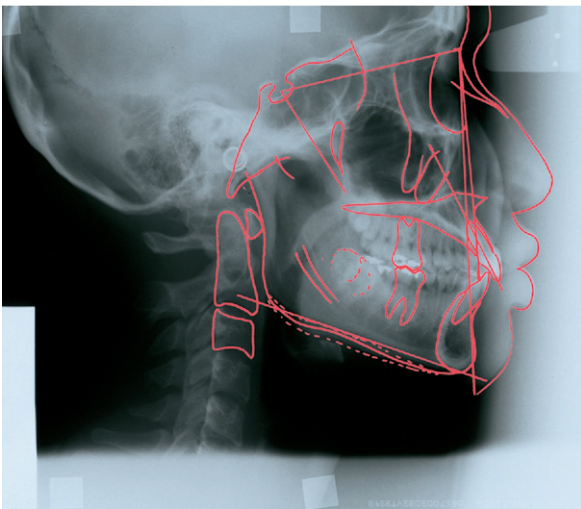


Fig 8. Posttreatment cephalometric tracing.

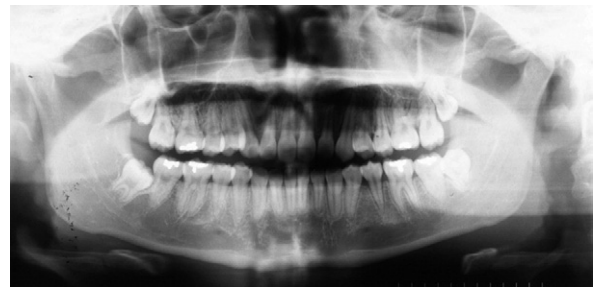

Fig 9. Posttreatment panoramic radiograph.

months and nights thereafter. The mandibular fixed 3 × 3 retainer was bonded on the canines only. The patient was instructed on home care and maintenance of the retainers. Her third molars are developing, and she was referred to an oral surgeon for evaluation for removal.

FINAL EVALUATION OF TREATMENT

A significant improvement in the occlusion was achieved; the objectives of increasing the vertical dimension and relieving the deep impinging overbite were attained (Fig 6). The Brodie bite on the left posterior segment was resolved via arch coordination. Gingival display upon smiling was also reduced. Our goal was to level the maxillary and mandibular incisors forward. This result was expected with the crowding and curve of Spee that were present. To prevent proclination of the maxillary and

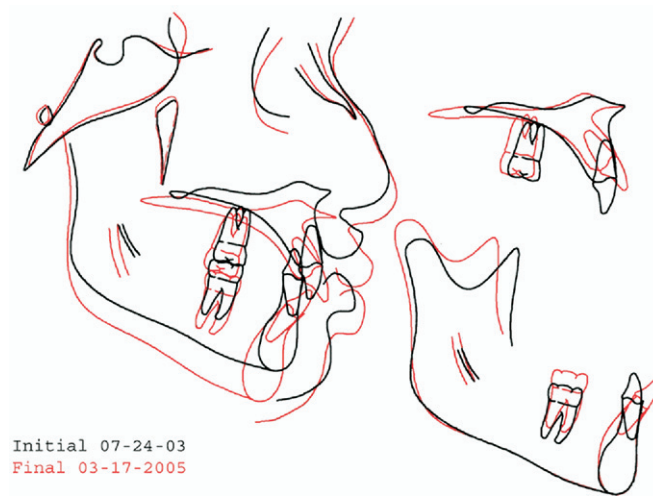


Fig 10. Superimposed cephalometric tracings.

mandibular incisors would have required extraction mechanotherapy that was not indicated with the severe overbite and the lack of vertical support. Arch coordination required constriction of the anterior segments in both arches. The panoramic radiograph shows an overangulated maxillary right canine that

could have been improved by better bracket position. Overall, there was significant improvement in both functional occlusion and esthetic balance. The prognosis for stability is good, and the dental corrections should be maintained with proper retainer cooperation.

Discrepancy Index for the Phase III Clinical Examination

The American Board of Orthodontics

DISCREPANCY INDEX

Case Category 4
 Total D.I. Score 22
 CAST EVAL 18

OVERJET

0 mm. (edge to edge) = 1 pt.
 1 - 3 mm. = 0 pts.
 3.1 - 5 mm. = 2 pts.
 5.1 - 7 mm. = 3 pts.
 7.1 - 9 mm. = 4 pts.
 > 9 mm. = 5 pts.

Negative OJ (x-bite) 1 pt. per mm. per tooth =
 Total = 3

OVERBITE

0 - 3 mm. = 0 pts.
 3.1 - 5 mm. = 2 pts.
 5.1 - 7 mm. = 3 pts.
 Impinging (100%) = 5 pts.
 Total = 5

ANTERIOR OPENBITE

0 mm. (edge to edge) = 1 pt.
 then 2 pts. per mm. per tooth
 Total = 0

LATERAL OPENBITE

2 pts. per mm. per tooth
 Total = 0

CROWDING

0 - 3 mm. = 1 pt.
 3.1 - 5 mm. = 2 pts.
 5.1 - 7 mm. = 4 pts.
 > 7 mm. = 7 pts.
 Total = 4

OCCLUSION

Class I to end on = 0 pts.
 End on Class II or III = 2 pts. per side
 Full Class II or III = 4 pts. per side
 Beyond Class II or III = 1 pt. per mm.
 Additional
 Total = 4

LINGUAL POSTERIOR X-BITE

1 pt. per tooth Total = 0

BUCCAL POSTERIOR X-BITE

2 pts. per tooth Total = 6

CEPHALOMETRICS

ANB > 5.5 or < -1.5 = 4 pts.
 Each Additional Degree = 1 pt.
 SN-GO-GN = 0 pts.
 27 deg. - 37 deg.
 SN-GO-GN > 37 deg. = 2 pts. per degree
 SN-GO-GN < 27 deg. = 1 pt. per degree
 IMPA > 98 deg. = 1 pt. per degree
 Total = 0

OTHER 2 pts. = 0
 (See instructions)

INDICATE PROBLEM _____

Fig 11. Discrepancy index form.