



Influence of patient head positioning on measured axial tooth inclination in panoramic radiography

Timothy C Hardy, Lokesh Suri & Paul Stark

To cite this article: Timothy C Hardy, Lokesh Suri & Paul Stark (2009) Influence of patient head positioning on measured axial tooth inclination in panoramic radiography, Journal of Orthodontics, 36:2, 103-110, DOI: [10.1179/14653120723013](https://doi.org/10.1179/14653120723013)

To link to this article: <https://doi.org/10.1179/14653120723013>



Published online: 16 Dec 2014.



Submit your article to this journal [↗](#)



Article views: 80



View related articles [↗](#)



Citing articles: 10 View citing articles [↗](#)

SCIENTIFIC
SECTIONInfluence of patient head positioning
on measured axial tooth inclination
in panoramic radiography

Timothy C Hardy, Lokesh Suri and Paul Stark

Tufts University School of Dental Medicine, Boston, MA

Objective: Panoramic radiographs are routinely used to assess the mesiodistal axial inclination of teeth (MDAI) in orthodontic treatment. These radiographs are sensitive to minor deviations from standard head position that result in image distortions. The aim of this study is to measure and quantify the changes in MDAI on panoramic radiograph resulting from changes in patient head position.

Materials and Methods: The testing device was a human skull with guide wires placed on the facial surface of the teeth and alveolar process along the long axis of each tooth. Panoramic radiographs were captured digitally with the orientation of the skull in Frankfurt horizontal plane parallel to the floor and with 1°, 2°, 5°, 7°, and 10° both superior and inferior rotations. The mesiodistal tooth angulations were determined using MIPAC software (DentalEye and LEAD Technologies, Inc. 2005).

Results: The more distal the position of the tooth in the arch the greater the change in MDAI with a change in vertical head position. A maximum change of approximately 10 degrees was observed in MDAI of both the maxillary and mandibular molars with a corresponding superior head tilt of 10 degrees. The Mandibular anteriors displayed significant inconsistencies in MDAI with both superior and inferior head tilt. A superior head tilt produced a greater change in mesiodistal angulation than did an inferior head tilt.

Conclusions: Accurately taken panoramic radiographs can serve as a convenient tool for evaluating the MDAI before, during and after orthodontic treatment. Additional radiographs are recommended for the mandibular anteriors.

Key words: Mesiodistal inclination, panoramic radiographs, diagnostics, tooth angulation, patient positioning

Received 24th April 2008; accepted 13th January 2009

Introduction

One of the aims in orthodontic treatment is to establish proper axial inclination of the teeth.^{1–6} Proper axial inclination of teeth aids in the correction of malocclusion, adequate disbursement of occlusal forces, appropriate tooth placement in the maxilla and mandible, proper interproximal contact, periodontal health, occlusal guidance and stability.^{4,6–8} Proper axial inclination is also one of the parameters for the evaluation of finished cases for board certification put forth by the American Board of Orthodontics.⁹ Panoramic radiographs are currently the mainstay for the assessment of the mesiodistal axial inclination (MDAI) of the teeth in the orthodontic office. These radiographs are used to guide the placement of the orthodontic brackets and place bends in the archwires during orthodontic treatment to achieve the desired axial tooth inclination.^{10–12}

Panoramic radiography (pantomography) was introduced in 1949 by Paatero in an attempt to accurately capture the entire dental arch in one image.^{5,13} The

method of obtaining the images was based on layer radiography whereby the source and the film moved in relation to the object to capture a narrow zone or area of interest known as the focal trough. The earlier machines allowed for two separate centres of rotation for either side of the face and were fraught with significant image distortions.¹⁴ Though it has been shown that panoramic radiography, even when taken in the ideal position, can have distortion,^{5,15} it is currently considered standard to use panoramic radiography in the assessment of mesiodistal tooth angulation¹⁶ and is the method most often used in orthodontic practice^{5,10–12,17} The relatively low radiation dosage, a broad projection with little superimposition, and simplicity in use have made these images routine.¹⁸

A panoramic machine must make complex movements to obtain a focal trough that includes the entire dentition. Due to this complex movement and significant variations in configuration of the dental arch of patients, distortions in the inclination of a tooth can arise.^{14,19} Most panoramic radiographs have a resultant

Address for correspondence: Timothy Charles Hardy, Tufts University School of Dental Medicine, 1 Kneeland Street, Boston, MA, 02111, USA.

Email: tictac2@gmail.com

© 2009 British Orthodontic Society

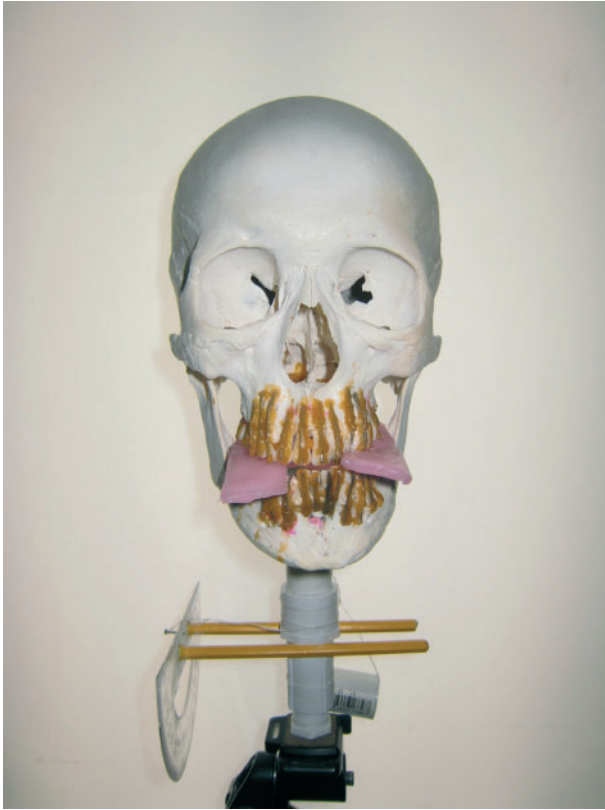

Figure 1 Skull apparatus

magnified and thus, distorted image.¹⁵ The distortions of teeth and other structures within the focal trough are affected by many variables, amongst which is patient head positioning.^{19–23}

The aim of this study was to measure and quantify the changes in mesiodistal tooth inclination that arise from the deviation of the head position from the ideal head position for panoramic radiography. This will help in quantifying the apparent change in mesiodistal angulation that arises from faulty head positioning while taking panoramic radiographs and avoiding artifactual interpretations. Identifying common distortions created by different patient positions during panoramic radiography will allow for a more accurate assessment of tooth inclination during orthodontic treatment.

Materials and methods

The testing device was a human skull mounted on a modified camera tripod to simulate head movements. A plastic cylinder was used to connect the skull to the camera tripod. The plastic cylinder was used to avoid artifacts on the radiographic image.¹⁰ Metal wires equal in length to the teeth were placed on the facial surface of




Figure 2 Close-up picture of the protractor used to determine head tilt of the skull apparatus

the teeth and alveolar process so that the wire paralleled the long axis of the tooth. A groove was made in the alveolar process buccal to the roots of the posterior teeth to place the wire as close as possible to the teeth. This allowed the metal wire to be parallel to the teeth and represent the long axis of the teeth more accurately. The radiographic projections of the metal wires were used as markers for determining tooth inclination. Sticky wax and super glue was used to reinforce the position of the wires. The mandible was positioned into protruded, edge-to-edge position to simulate patient position while obtaining a panoramic radiograph. This position was held in place using bite wax. The mandible was secured to the skull using rubber bands connected to small screws placed in the palate and mandible. The above apparatus will be referred to as the 'skull apparatus' (Figure 1).

The skull apparatus was radiographed using a *Kodak 8000C Digital Panoramic and Cephalometric System* panoramic machine. The Kvp and exposure time were adjusted to obtain a diagnostically acceptable image of the skull apparatus. The skull apparatus was first radiographed in the ideal position, where the Frankfurt Horizontal is parallel to the floor. It was then radiographed with 1, 2, 5, 7 and 10° superior and inferior rotations. This was repeated three times to obtain a total of four radiographs in each head position. The head positioning indicator lights in the Kodak panoramic unit were used to position the skull apparatus in the ideal head position, aligning the Frankfurt Horizontal with the horizontal head positioning light. The angles for head tilt were determined using a protractor and plumb line affixed on the skull apparatus with 90° set for the base line ideal position (Figure 2).

The maxillary and mandibular tooth angulations were measured using the horizontal plane of the captured

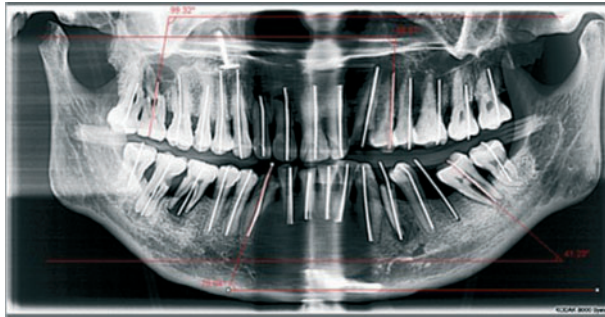


Figure 3 Radiograph of skull apparatus with examples of the measured Mesiodistal ascal inclination

image as the reference plane. The radiographic image of the wire was used as a guide to determine the long axis of the tooth. The radiographic image of the wire was projected onto the horizontal reference plane of the image and the mesio-occlusal angle was then measured for both the maxillary and the mandibular teeth. The angulations were measured using MIPAC (DentalEye and LEAD Technologies, Inc., 2005) software (Figure 3).

The values obtained were entered into a Microsoft Excel spreadsheet and analysed for significance in differences of measured tooth tip. The measured tooth tip was compared to when the skull is in the 'ideal' patient position. As the results are normally distributed the statistical significance between groups was determined using a paired t-test.

Measurement error

In order to account for intra-operator error the skull apparatus was repositioned within the panoramic unit between each radiograph. In addition, each set of angles radiographed were taken at least several days apart. The intra-class correlation was calculated and was found to be 0.874.

Results

The mean angle measured and its associated change in measured tooth tip for superior head tilts is given in Table 1. The mean angle measured and its associated change in measured tooth tip for inferior head tilts is given in Table 2. The mean is the average of four radiographs. Only angles with a significant difference from ideal were displayed ($P < 0.05$). The angle taken is the mesio-occlusal angle formed between the horizontal plane of the image and the long axis of the tooth. A tooth tip of greater than 90° indicates a mesial inclination to the root with the apical portion of the root more mesial to the crown. A negative difference

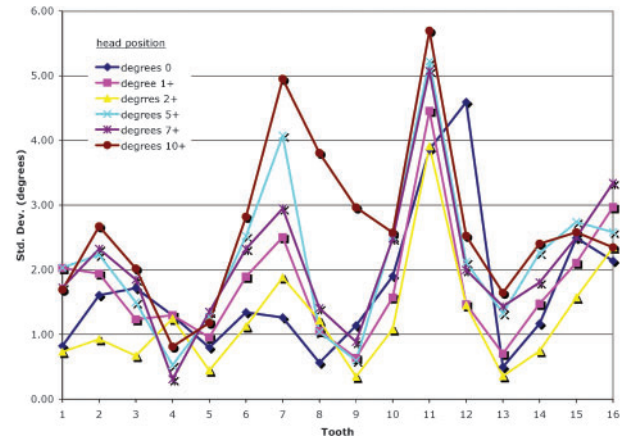


Figure 4 Variations in mesiodistal tooth angulations of the maxillary arch with changes in superior patient head tilt. The angle measured is the mesio-occlusal angle formed by the long axis of the tooth and the computer's horizontal. A negative difference refers to a more distal tip of the root

refers to a more distal tip of the root. The greatest difference in tooth tip when compared to ideal, or 0° head tilt, was found in the most posterior teeth. Greater changes were found when there was a superior head tilt versus an inferior head tilt. The maximum change in tooth tip was approximately 12° increased distal tip in tooth number 16 with a 10° superior head tilt.

Graphs of changes in tooth tip can be seen in Figures 4–7. A superior head tilt of 2° or more showed significant ($P < 0.01$) changes in mesiodistal tooth angulations in maxillary and mandibular molars. An inferior head tilt of 5° was required to show significant ($P < 0.05$) changes in mesiodistal tooth angulations in maxillary molars. An inferior head tilt of 7° was

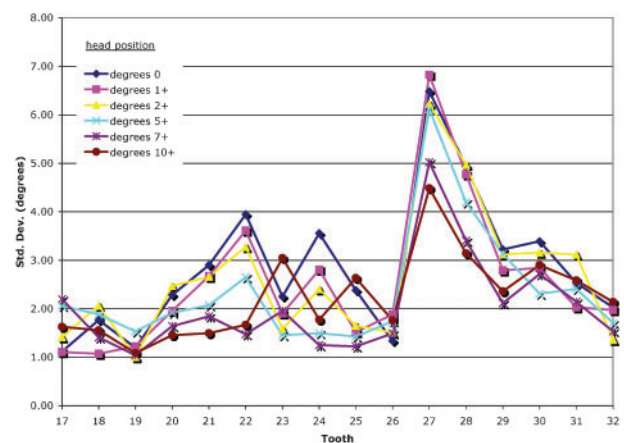


Figure 5 Variations in mesiodistal tooth angulations of the mandibular arch with changes in superior patient head tilt. The angle measured is the mesio-occlusal angle formed by the long axis of the tooth and the computer's horizontal. A positive difference refers to a more mesial tip of the root

Table 1 Results showing tooth tip angulation (in degrees) and differences for superior head tilt with statistical significance ($P < 0.05$).

Average		+1°			+2°			+5°			+7°			+10°			
Tooth	Tooth ID	Angle*	Difference	P value	Angle*	Difference	P value	Angle*	Difference	P value	Angle*	Difference	P value	Angle*	Difference	P value	
UR8	1	115.32	113.75	-1.57	0.166	113.02	-2.295	0.010	109.32	-5.995	0.008	108.64	-6.680	0.002	104.39	-10.933	0.002
UR7	2	102.11	101.16	-0.945	0.026	99.86	-2.245	0.010	96.36	-5.745	0.005	93.73	-8.377	0.021	92.42	-9.685	0.002
UR6	3	94.72	92.14	-2.58	0.091	91.43	-3.29	0.068	88.48	-6.235	0.012	88.10	-6.613	0.015	84.76	-9.958	0.007
UR5	4	96.65	95.86	-0.78	0.069	94.99	-1.658	0.012	93.08	-3.572	0.005	92.08	-4.568	0.004	90.17	-6.480	0.003
UR4	5	91.33	90.29	-1.037	0.018	89.44	-1.885	0.022	87.10	-4.228	0.010	86.81	-4.515	0.003	84.32	-7.008	0.002
UR3	6	88.53	87.74	-0.79	0.073	86.93	-1.605	0.007	84.82	-3.715	0.027	84.80	-3.735	0.005	82.00	-6.528	0.008
UR2	7	90.42	88.70	-1.72	0.112	88.99	-1.43	0.076	86.29	-4.13	0.106	86.80	-3.623	0.032	83.26	-7.160	0.044
UR1	8	90.42	89.37	-1.05	0.187	89.13	-1.29	0.176	88.85	-1.57	0.090	88.72	-1.71	0.113	86.64	-3.79	0.160
UL1	9	89.32	89.84	0.53	0.459	89.74	0.43	0.433	89.32	0.01	0.989	89.32	0.01	0.996	88.24	-1.08	0.369
UL2	10	91.62	91.00	-0.62	0.255	90.59	-1.03	0.143	88.80	-2.82	0.057	88.64	-2.980	0.003	85.35	-6.268	0.067
UL3	11	82.37	80.98	-1.385	0.024	80.79	-1.578	0.031	77.28	-5.090	0.018	77.58	-4.793	0.009	74.12	-8.248	0.005
UL4	12	90.98	87.12	-3.86	0.218	86.96	-4.02	0.196	83.63	-7.34	0.092	82.94	-8.033	0.049	80.81	-10.168	0.042
UL5	13	90.69	89.44	-1.245	0.032	88.90	-1.788	0.013	86.02	-4.663	0.007	85.07	-5.613	0.005	82.98	-7.710	0.003
UL6	14	89.48	88.33	-1.158	0.035	87.73	-1.758	0.020	83.87	-5.618	0.003	83.38	-6.105	0.002	79.78	-9.708	0.001
UL7	15	94.04	92.87	-1.18	0.071	91.91	-2.132	0.042	88.27	-5.770	0.001	87.43	-6.610	0.000	84.06	-9.985	0.000
UL8	16	102.76	100.81	-1.95	0.121	99.36	-3.395	0.043	94.73	-8.030	0.004	94.42	-8.335	0.005	90.35	-12.403	0.001
LL8	17	50.83	51.99	1.16	0.086	53.96	3.128	0.001	57.29	6.458	0.003	58.59	7.758	0.002	60.78	9.945	0.000
LL7	18	38.64	40.00	1.36	0.151	41.60	2.968	0.009	44.80	6.168	0.001	47.37	8.735	0.000	49.11	10.478	0.000
LL6	19	53.42	54.56	1.14	0.113	55.87	2.447	0.001	58.38	4.962	0.000	60.77	7.348	0.001	62.33	8.915	0.000
LL5	20	60.43	61.66	1.228	0.050	63.04	2.613	0.005	65.86	5.430	0.001	68.05	7.625	0.001	69.33	8.903	0.000
LL4	21	73.34	74.46	1.12	0.057	75.55	2.208	0.020	77.63	4.295	0.008	79.45	6.110	0.002	80.76	7.425	0.003
LL3	22	81.65	82.97	1.325	0.028	83.91	2.265	0.071	85.44	3.795	0.099	87.74	6.095	0.016	89.02	7.373	0.054
LL2	23	94.27	95.14	0.86	0.213	94.78	0.51	0.417	96.52	2.25	0.160	97.35	3.07	0.169	98.75	4.48	0.167
LL1	24	87.70	88.60	0.90	0.256	87.96	0.26	0.804	88.93	1.23	0.512	89.80	2.11	0.176	91.37	3.68	0.231
LR1	25	91.87	91.54	-0.33	0.635	91.50	-0.37	0.586	90.40	-1.47	0.349	90.53	-1.34	0.344	90.26	-1.61	0.493
LR2	26	95.71	93.44	-2.28	0.159	94.71	-1.00	0.416	94.96	-0.75	0.611	95.06	-0.65	0.527	94.67	-1.05	0.495
LR3	27	73.18	73.65	0.47	0.692	75.63	2.45	0.055	76.59	3.41	0.069	79.06	5.887	0.010	79.79	6.618	0.010
LR4	28	69.93	70.76	0.83	0.287	72.80	2.88	0.010	74.18	4.250	0.007	76.43	6.500	0.005	77.67	7.748	0.006
LR5	29	71.81	72.83	1.02	0.113	74.21	2.393	0.004	76.65	4.835	0.001	78.18	6.363	0.002	80.08	8.265	0.002
LR6	30	58.28	59.56	1.28	0.154	60.48	2.20	0.052	63.21	4.930	0.005	65.73	7.445	0.002	67.95	9.665	0.002
LR7	31	58.99	60.26	1.278	0.041	62.21	3.223	0.013	64.87	5.885	0.000	67.55	8.560	0.000	69.73	10.748	0.001
LR8	32	67.69	68.82	1.128	0.011	70.39	2.698	0.011	73.43	5.740	0.000	75.74	8.055	0.002	78.26	10.575	0.003

Angle taken is the mesial-occlusal angle formed between the computer's horizontal and the long axis of the tooth. A mesiodistal tooth angulation of greater than 90° indicates a mesial inclination to the root.

*Based on four measurements for each head position.

Table 2 Results showing tooth tip angulation (in degrees) and differences for inferior head tilt with statistical significance ($P<0.05$).

Average		-1°			-2°			-5°			-7°			-10°		
Tooth	Tooth ID	Angle*	Difference	P value	Angle*	Difference	P value	Angle*	Difference	P value	Angle*	Difference	P value	Angle*	Difference	P value
UR8	1	115.32	116.70	1.38	0.161	115.82	0.50	0.629	119.26	3.940	0.009	119.56	4.242	123.11	7.787	0.002
UR7	2	102.11	103.40	1.29	0.158	102.83	0.73	0.561	105.45	3.340	0.013	107.01	4.908	109.38	7.270	0.002
UR6	3	94.72	94.95	0.23	0.805	94.70	-0.01	0.990	97.01	2.290	0.030	98.57	3.857	100.74	6.025	0.009
UR5	4	96.65	96.91	0.26	0.057	97.64	0.987	0.006	99.29	2.643	0.005	100.52	3.870	102.29	5.638	0.003
UR4	5	91.33	91.76	0.44	0.474	91.65	0.33	0.644	93.49	2.17	0.070	94.51	3.182	96.29	4.967	0.022
UR3	6	88.53	89.44	0.91	0.233	89.00	0.47	0.504	90.74	2.208	0.019	91.48	2.950	93.21	4.680	0.014
UR2	7	90.42	90.92	0.50	0.560	89.94	-0.48	0.722	91.20	0.78	0.293	92.40	1.97	93.19	2.77	0.066
UR1	8	90.42	90.64	0.22	0.571	90.09	-0.33	0.348	90.63	0.21	0.577	91.21	0.78	91.65	1.230	0.049
UL1	9	89.32	89.40	0.09	0.827	89.28	-0.03	0.942	89.96	0.65	0.332	90.19	0.88	90.71	1.39	0.058
UL2	10	91.62	92.49	0.87	0.360	90.80	-0.82	0.671	92.87	1.25	0.225	93.16	1.54	94.25	2.63	0.111
UL3	11	82.37	84.10	1.73	0.135	82.70	0.33	0.756	84.82	2.452	0.029	86.04	3.675	88.02	5.650	0.015
UL4	12	90.98	89.21	-1.77	0.542	89.26	-1.71	0.601	91.08	0.10	0.968	92.20	1.22	93.66	2.68	0.320
UL5	13	90.69	90.98	0.30	0.583	91.36	0.67	0.228	93.65	2.960	0.013	94.49	3.800	96.11	5.425	0.005
UL6	14	89.48	90.53	1.05	0.060	90.85	1.365	0.011	92.93	3.443	0.003	94.03	4.548	96.47	6.983	0.002
UL7	15	94.04	95.44	1.40	0.099	95.43	1.39	0.052	97.79	3.753	0.005	99.66	5.615	102.45	8.405	0.004
UL8	16	102.76	103.65	0.89	0.222	103.14	0.39	0.651	106.11	3.355	0.005	107.80	5.043	111.76	9.005	0.003
LL8	17	50.83	50.90	0.07	0.951	50.82	-0.02	0.987	48.48	-2.348	0.042	47.32	-3.510	43.77	-7.060	0.001
LL7	18	38.64	39.25	0.61	0.727	38.91	0.27	0.839	36.16	-2.47	0.146	35.36	-3.273	31.25	-7.385	0.009
LL6	19	53.42	53.63	0.21	0.890	53.62	0.20	0.821	51.24	-2.18	0.054	50.97	-2.45	47.19	-6.233	0.002
LL5	20	60.43	61.41	0.98	0.551	61.12	0.69	0.563	58.32	-2.11	0.112	57.83	-2.60	54.63	-5.798	0.006
LL4	21	73.34	74.06	0.72	0.650	73.70	0.37	0.795	71.52	-1.82	0.178	71.17	-2.17	68.65	-4.693	0.021
LL3	22	81.65	83.43	1.78	0.540	81.41	-0.23	0.931	80.28	-1.36	0.456	80.35	-1.30	79.23	-2.41	0.338
LL2	23	94.27	94.00	-0.28	0.904	92.99	-1.28	0.627	92.59	-1.68	0.441	92.34	-1.93	93.22	-1.05	0.552
LL1	24	87.70	88.20	0.51	0.861	86.98	-0.72	0.836	86.34	-1.36	0.691	87.44	-0.25	87.66	-0.04	0.990
LR1	25	91.87	92.46	0.59	0.794	92.39	0.52	0.809	93.48	1.61	0.470	92.78	0.91	91.04	-0.83	0.710
LR2	26	95.71	95.92	0.21	0.895	95.13	-0.59	0.596	95.86	0.14	0.934	94.34	-1.37	93.19	-2.52	0.403
LR3	27	73.18	76.86	3.69	0.084	73.15	-0.03	0.991	73.32	0.14	0.908	72.24	-0.93	70.92	-2.26	0.312
LR4	28	69.93	72.14	2.22	0.204	70.29	0.36	0.833	69.22	-0.71	0.408	68.06	-1.87	66.21	-3.720	0.060
LR5	29	71.81	73.42	1.61	0.220	72.25	0.44	0.737	71.11	-0.70	0.382	69.91	-1.91	67.52	-4.298	0.045
LR6	30	58.28	60.11	1.83	0.181	59.00	0.72	0.634	56.22	-2.07	0.149	55.82	-2.47	52.54	-5.745	0.015
LR7	31	58.99	60.17	1.18	0.481	59.69	0.71	0.575	57.03	-1.96	0.131	55.69	-3.29	52.77	-6.220	0.010
LR8	32	67.69	67.97	0.28	0.833	67.85	0.16	0.892	64.22	-3.47	0.160	63.83	-3.855	60.83	-6.858	0.005

Angle taken is the mesial-occlusal angle formed between the computer's horizontal and the long axis of the tooth. A mesiodistal tooth angulation of greater than 90° indicates a mesial inclination to the root.

*Based on four measurements for each head position.

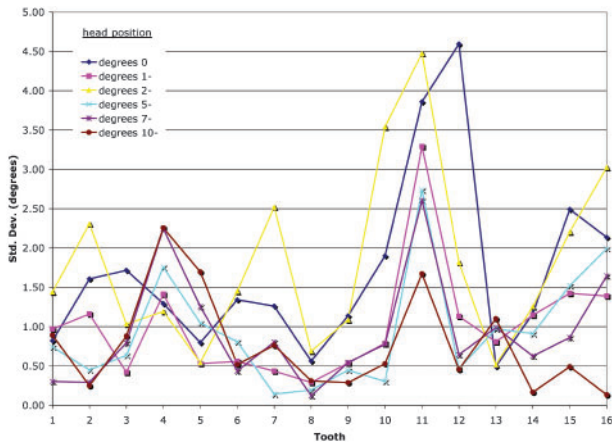


Figure 6 Variations in mesiodistal tooth angulations of the maxillary arch with changes in inferior patient head tilt. The angle measured is the mesio-occlusal angle formed by the long axis of the tooth and the computer's horizontal. A positive difference refers to a more mesial tip of the root

required to show significant ($P < 0.05$) changes in mesiodistal tooth angulations in mandibular molars. A mere 1° superior head tilt resulted in statistically significant changes in tooth tip of the premolar region ($P < 0.05$). A 2° inferior head tilt showed significant results in the premolar region ($P < 0.05$). When analysing the mandibular anteriors no statistical significance in changes in tooth tip with changes in head tilt were found ($P > 0.2$). Maxillary and mandibular anteriors showed no statistically significant changes in the mesiodistal tooth angulation.

Discussion

In orthodontics, panoramic radiographs are routinely used for evaluation of the axial tooth inclinations.¹⁰⁻¹² Various bracket prescriptions have been developed for orthodontic treatment to attain the desired tooth inclinations. Frequently mid treatment panoramic radiographs are used by the orthodontist to either reposition brackets or place bends in the wire for teeth that do not display acceptable axial inclination. The panoramic radiograph is known to be significantly influenced by minor deviations from ideal head positioning. This study was undertaken to ascertain the degree of deviation that resulted in the observed tooth inclination from deviations in head position.

The skull apparatus used in this study was found to be a reliable means to produce clinically realistic images with adequate representation of anatomical landmarks and a means to measure mesiodistal tooth angulations. It also allowed for clinical simulation of variations in head positioning and a means to take multiple radiographs without patient exposure. The wires placed

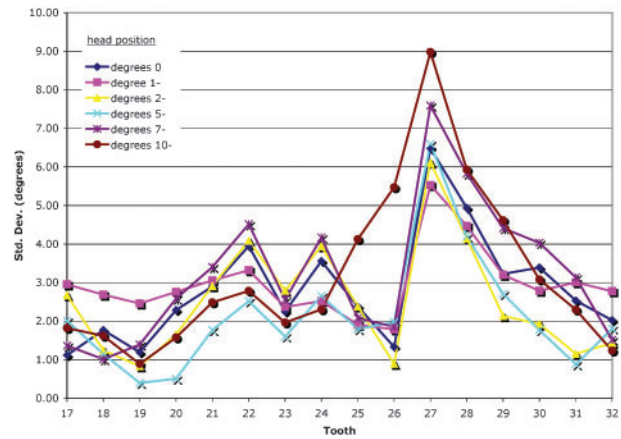


Figure 7 Variations in mesiodistal tooth angulations of the mandibular arch with changes in inferior patient head tilt. The angle measured is the mesio-occlusal angle formed by the long axis of the tooth and the computer's horizontal. A negative difference refers to a more distal tip of the root

on the facial surface of the teeth allowed for accurate, consistent measurements eliminating variations in radiographic projection of tooth anatomy. In addition the results of this study can be applied to various models of panoramic machines since different panoramic units have been found to produce similar results when assessing mesiodistal tooth angulations.⁵

The results of this study show that changes in superior-inferior patient head positions created statistically significant changes in tooth tip. Significant changes were first seen in maxillary and mandibular premolars with a 1° superior head tilt and in maxillary and mandibular premolars with a 2° inferior head tilt. These low values of changes in head tilt that result in significant changes in MDAI confirm the sensitivity of panoramic units when capturing the premolar regions as has been reported in previous studies.^{10,18,19} The standard deviation was found to be higher in the canine-premolar region of the upper left and lower right side. No obvious deformity in the skull could account for the high standard deviation localized to these areas. Although a rotation or a tilt of the skull may produce such variations in measurement it was aimed to position the skull apparatus with great accuracy and was discussed in the error of method. After visual inspection of the skull apparatus' arch form, teeth positioning and angulation, no apparent source for this error was found. It has been found that the complexity of movement of the X-ray source and film while capturing this region can cause significant inherent distortion,^{10,18,19} which might account for the results found.

Significant changes were first seen with changes in superior head tilt. For example, maxillary and mandibular molars showed significant changes with a superior

head tilt of 2° , whereas an inferior head tilt of 5° was required to show significant changes in the maxillary molars. This shows that mesiodistal tooth angulation is more sensitive to superior head tilts as compared to inferior head tilts. Crown and root angulations, tooth size, rotations and torque create changes in positioning within the focal trough.^{5,14,23} This could have had a more significant effect on tooth tip with superior head tilts, than did inferior head tilts. In a previous study on the common positioning and technical errors in panoramic radiography they found that the majority of malpositioned patients had an inferior head tilt (14% of all patients being positioned in the panoramic unit) and 1% of patients had their head tilted superiorly.^{20,22}

The two-dimensional plane for molar tooth tip is in approximately the same plane as superior-inferior patient head positioning. This creates a direct effect on tooth tip of posteriors when there are changes in superior-inferior head positioning. A superior head tilt creates a more distal tip of maxillary molar roots and a more mesial tip of mandibular molar roots, whereas an inferior tilt creates a more mesial tip of maxillary molar roots and a more distal tip of mandibular molar roots. These changes in tooth tip, as seen in Figures 4–7, are approximately equal to the changes in patient positioning. More significant changes were seen in the posterior teeth and decreased the more anterior the tooth. This was also seen in a study performed by Samawi and Burke.¹⁹

The two-dimensional plane for premolar and anterior tooth tip is not in the same plane as superior-inferior patient head positioning. This creates an indirect effect on tooth tip when there are changes in head positioning, mainly due to distortion. However, trends in this distortion can be found, in Figures 4–7. A superior head tilt created distortions that caused the maxillary premolars and anteriors to have a more distal root tip on panoramic radiographic assessment, whereas an inferior head tilt created a more mesial root tip. As seen in Figures 5 and 7, no such trends for the anteriors can readily be seen. Panoramic radiographic assessment of mandibular premolars showed a more mesial tip with changes in superior head tilt and a more distal root tip with inferior head tilts. These distortions can be explained by where the endpoints of the tooth are within the focal trough. As explained by Tronje *et al.*, tooth endpoints that are located at different spots within the focal trough will be projected onto the film at different distances from the centre point of the tooth. Since the tooth is inclined, part of the tooth will show up with an enlarged image angle and the other half with a diminished image angle.²⁴ As the head position is changed, so is the tooth inclination within the focal trough. This results in a change in measured mesiodistal tooth inclination.

Clinically, it has been found that variations over 2.5° between a tooth and reference plane create significant changes during assessment of tooth angulation on a panoramic radiograph.^{5,18,19,24} Using this information, a superior head tilt of 2° and an inferior head tilt of 5° would allow for variations in assessment of tooth tip. Other authors have found that variations up to 5° in mesiodistal tooth angulation do not alter the treatment plan during assessment of tooth angulation on a panoramic radiograph.^{12,25–27} These reports suggest that significant changes in assessment of tooth tip would not result unless the patient was malpositioned 5° or more in a superior head tilt or at least 7° in an inferior head tilt. Head tilts of up to 5° have been proposed to be the upper limits of improper patient positioning seen in the dental field.¹⁰

Often there are crown-root angulations, rotations, crowding and/or spacing found in a patient's dentition. These malpositioned teeth are a variable that can influence the measured axial inclination in a panoramic radiograph. Combining the effects of malpositioned teeth with improper patient placement in a panoramic unit has the potential to greatly alter the axial inclination measured on a panoramic radiograph. The effect of crown-root angulations, crowding and/or spacing on assessing tooth tip in panoramic radiographs was not within the realm of this study, but is something that should be looked at in future studies.

Variations in the size and shape of the arches, as well as variations in the positioning of teeth within different patients can affect geometry of the arches within the focal trough, thus affecting the distortions produced.^{5,18,21} Therefore, the results of this study cannot be directly applied to every patient's radiographic analysis.

As a means to assess the accuracy of measuring tooth tip on a panoramic radiograph, comparison with the measurements found using computed tomography (CT) has recently been performed and showed that panoramic radiography did not accurately depict tooth tip.¹⁵ The routine use of CT, however, presents concerns such as increased patient exposure to radiation and costs to both practitioner and patient, which may limit the use of CT. More information would be an indication for the use of CT in the orthodontic clinic. Panoramic radiography has and may continue to prove to be an effective tool in the orthodontic evaluation of a patient.

Conclusion

- Accurately taken panoramic radiographs are currently a practical means of evaluating mesiodistal tooth angulations. However, the assessment, while

ascertaining the general state of the dentition, should be performed with prudence.

- Even with ideally positioned patients distortions may be present. These distortions can easily be exacerbated by improper patient positioning.
- Special care should be taken when evaluating posterior teeth and when evaluating root angulation of mandibular anteriors. Additional radiographs may be necessary for evaluation of root angulation of the mandibular anteriors.
- Further studies are necessary to evaluate the influence of crown-root angulations, rotations, crowding and spacing on the change in tooth inclination observed on panoramic radiographs.

Contributor statement

T.C. Hardy was responsible for study design; obtaining funding; data collection; analysis; and drafting, critical revision, and final approval of the article. Lokesh Suri was responsible for study design; obtaining funding; logistic, administrative, and technical support and data interpretation; drafting, critical revision, and final approval of the article. Paul Stark was responsible for logistic, administrative, and technical support and data interpretation. Lokesh Suri is the guarantor.

References

1. Nance HN. The limitations of orthodontic treatment. Part II. *Am J Orthod Oral Surg* 1947; **33**: 253–301.
2. Dewel BF. Clinical observations on the axial inclination of teeth. *Am J Orthod* 1949; **35**: 98–115.
3. Dempster WT, Adams WJ, Duddles RA. Arrangement in the jaws of the roots of teeth. *J Am Dent Assoc* 1963; **67**: 779–97.
4. Andrews LF. The six keys to normal occlusion. *Am J Orthod* 1972; **62**(3): 296–309.
5. Mckee I, Williamson P, Lam E, Heo G, Glover K, Major P. The accuracy of 4 panoramic units in the projection of mesiodistal tooth angulations. *Am J Orthod Dentofac Orthoped* 2002; **121**(2): 166–75.
6. Ash MM. Occlusion. In *Wheeler's Dental Anatomy, Physiology, and Occlusion*. Philadelphia, PA: WB Saunders, 1993, 414–70.
7. Artun J, Kokich VG, Osterberg SK. Long-term effect of root proximity on periodontal health after orthodontic treatment. *Am J Orthod Dentofacial Orthop* 1987; **91**(2): 125–30.
8. Ingervall B. Functionally optimal occlusion: the goal of orthodontic treatment. *Am J Orthod* 1976; **70**(1): 81–90.
9. Grading system for dental casts and panoramic radiographs, available at: <http://www.americanboardortho.com/professionals/clinicalexam/casereportpresentation/GradingSystem/gsys6.aspx> (accessed 15 July 2007).
10. Mckee I, Glover K, Williamson P, Lam E, Heo G, Major P. The effect of vertical and horizontal head positioning in panoramic radiography on mesiodistal tooth angulations. *Angle Orthod* 2001; **71**(6): 442–51.
11. Lucchesi M, Wood R, Nortje C. Suitability of the panoramic radiograph for assessment of mesiodistal angulation of teeth in the buccal segments of the mandible. *Am J Orthod Dentofac Orthop* 1988; **94**: 303–10.
12. Ursi W, Almeida R, Tavano O, Henriques J. Assessment of mesiodistal axial inclination through panoramic radiography. *J Clin Orthod* 1990; **24**: 166–73.
13. Paatero YV. A new tomographical method for radiographing curved outer surfaces. *Acta Radiol* 1949; **32**: 177–84.
14. Rejebian G. A statistical correlation of individual tooth size distortions on orthopantomographic radiograph. *Am J Orthod* 1979; **75**: 525–34.
15. Peck J, Sameshima GT, Miller A, Worth P, Hatcher DC. Mesiodistal root angulation using panoramic and cone beam CT. *Angle Orthod* 2007; **77**(2): 206–13.
16. Owens A, Johal A. Near-end treatment panoramic radiograph in the assessment of mesiodistal root angulation. *Angle Orthod* 2008; **78**(3): 475–81.
17. Almeida-Pedrin RR, Pinzan A, Almeida RR, Ursi W, Almeida MR. Panoramic evaluation of mesiodistal axial inclinations of maxillary anterior teeth in orthodontically treated subjects. *Am J Orthod Dentofac Orthop* 2006; **130**(1): 56–61.
18. Samawi S, Burke P. Angular distortion in the orthopantomogram. *Brit J Orthod* 1984; **11**: 100–07.
19. White S, Pharoah M. Panoramic radiography. In *Oral Radiology, Principles and Interpretation*. St. Louis, MO: Mosby, 2004, 191–209.
20. Rowse C. Notes on interpretation of the orthopantomogram. *Brit Dent J* 1971; **130**: 425–34.
21. Christen A, Segreto V. Distortion and artifacts encountered in panorex radiography. *J Am Dent Assoc* 1968; **77**: 1096–101.
22. Schiff T, D'Ambrosio J, Glass B, Langlais R, McDavid W. Common positioning and technical errors in panoramic radiography. *J Am Dent Assoc* 1986; **113**: 422–26.
23. Lund T, Manson-Hing L. Relations between tooth positions and focal troughs of panoramic machines. *Oral Surg* 1975; **40**(2): 285–93.
24. McDavid W, Tronje G, Welander U, Morris C, Nummikoski P. Imaging characteristics of seven panoramic X-ray units. *Dentomaxillofac Radiol* 1985; **8**(suppl): 1–68.
25. Stromatas S, Geenty J, Petocz P, Darendeliler M. Accuracy of linear and angular measurements on panoramic radiographs taken at various positions *in vitro*. *Euro J Orthod* 2002; **24**: 43–52.
26. Tronje G, Welander U, McDavid W, Morris C. Image distortion in rotational panoramic radiography, III, inclined objects. *Acta Radiologica Diag* 1981; **22**: 585–92.
27. Samfors K, Welander U. Angle distortion in narrow beam rotation radiography. *Acta Radiologica Diag* 1974; **15**: 570–76.